



Owner's Copy

PennHIP Report

Referring Veterinarian: Dr Karen Taylor	Clinic Name: Animal Medical Center of Brooksville
Email: reception@animal-medical-center.com	Clinic Address: 22273 Cortez Blvd Brooksville, FL 34601
	Phone: (352) 796-7559
	Fax: (352) 796-1230

Patient Information

Client: Warfel, Victoria	Tattoo Num:
Patient Name: Ginger	Patient ID: 4272
Reg. Name: Tramin Ethnic Style	Registration Num: SS13666101
PennHIP Num: 154458	Microchip Num: 900085000166252
Species: Canine	Breed: GOLDEN RETRIEVER
Date of Birth: 12 Apr 2017	Age: 47 months
Sex: Female	Weight: 65.8 lbs/29.8 kgs
Date of Study: 23 Mar 2021	Date Submitted: 23 Mar 2021
Date of Report: 24 Mar 2021	

Findings

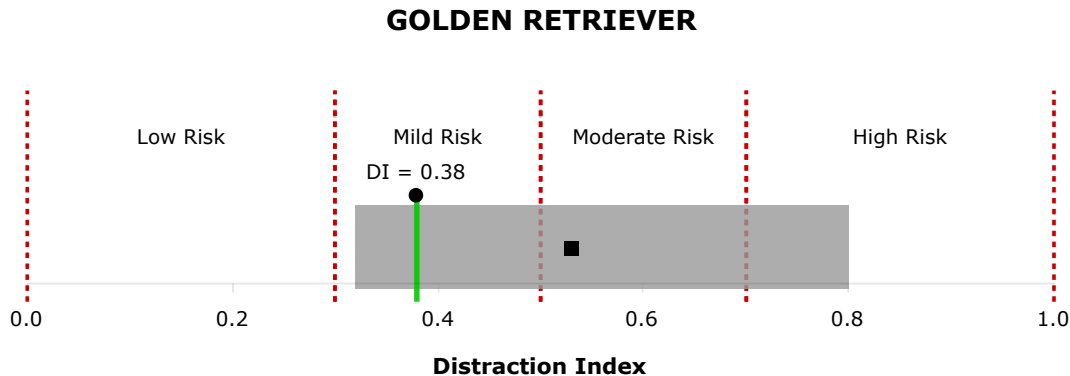
Distraction Index (DI): Right DI = 0.31, Left DI = 0.38.
Osteoarthritis (OA): No radiographic evidence of OA for either hip.
Cavitation/Other Findings: No cavitation present.

Interpretation

Distraction Index (DI): The laxity ranking is based on the hip with the greater laxity (larger DI). In this case the DI used is 0.38.

OA Risk Category: The DI is between 0.31 and 0.49. This patient is at mild risk for hip OA.

Distraction Index Chart:



BREED STATISTICS: This interpretation is based on a cross-section of 22042 canine patients of the GOLDEN RETRIEVER breed in the AIS PennHIP database. The gray strip represents the central 90% range of DIs (0.32 - 0.80) for the breed. The breed average DI is 0.53 (solid square). The patient DI is the solid circle (0.38).

SUMMARY: The degree of laxity (DI = 0.38) falls within the central 90% range of DIs for the breed. This amount of hip laxity places the hip at a mild risk to develop hip OA. **No radiographic evidence of OA for either hip.**