

PennHIP Report

Referring Veterinarian: Dr Karen Taylor	Clinic Name: Animal Medical Center of Brooksville
Email: reception@animal-medical-center.com	Clinic Address: 22273 Cortez Blvd Brooksville, FL 34601
	Phone:
	Fax:

Patient Information

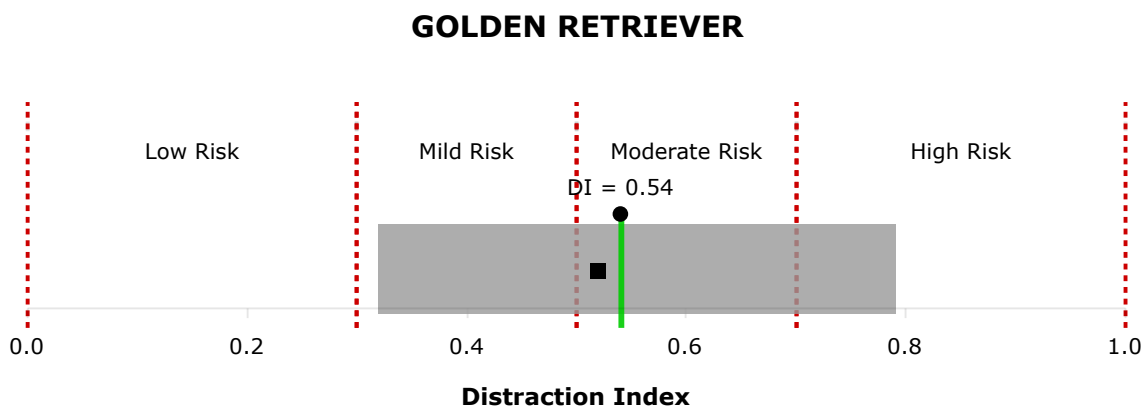
Client: Warfel, Victoria	Tattoo Num:
Patient Name: Sorcha	Patient ID: 5941
Reg. Name: Fantasia's Sorcerer Apprentice Of HSD	Registration Num: SS31553501
PennHIP Num: 196054	Microchip Num: 956000013869946
Species: Canine	Breed: GOLDEN RETRIEVER
Date of Birth: 23 Nov 2022	Age: 12 months
Sex: Female	Weight: 62 lbs/28.1 kgs
Date of Study: 27 Nov 2023	Date Submitted: 27 Nov 2023
Date of Report: 28 Nov 2023	

Findings

Distraction Index (DI): Right DI = 0.54, Left DI = 0.54.
Osteoarthritis (OA): No radiographic evidence of OA for either hip.
Cavitation/Other Findings: No cavitation present.

Interpretation

Distraction Index (DI): The laxity ranking is based on the hip with the greater laxity (larger DI). In this case the DI used is 0.54.
 OA Risk Category: The DI is between 0.50 and 0.69. This patient is at moderate risk for hip OA.
 Distraction Index Chart:



BREED STATISTICS: This interpretation is based on a cross-section of 26479 canine patients of the GOLDEN RETRIEVER breed in the AIS PennHIP database. The gray strip represents the central 90% range of DIs (0.32 - 0.79) for the breed. The breed average DI is 0.52 (solid square). The patient DI is the solid circle (0.54).

SUMMARY: The degree of laxity (DI = 0.54) falls within the central 90% range of DIs for the breed. This amount of hip laxity places the hip at a moderate risk to develop hip OA. **No radiographic evidence of OA for either hip.**