

PennHIP Report

Referring Veterinarian: Dr Karen Taylor	Clinic Name: Animal Medical Center of Brooksville
Email: reception@animal-medical-center.com	Clinic Address: 22273 Cortez Blvd Brooksville, FL 34601
	Phone: (352) 796-7559
	Fax: (352) 796-1230

Patient Information

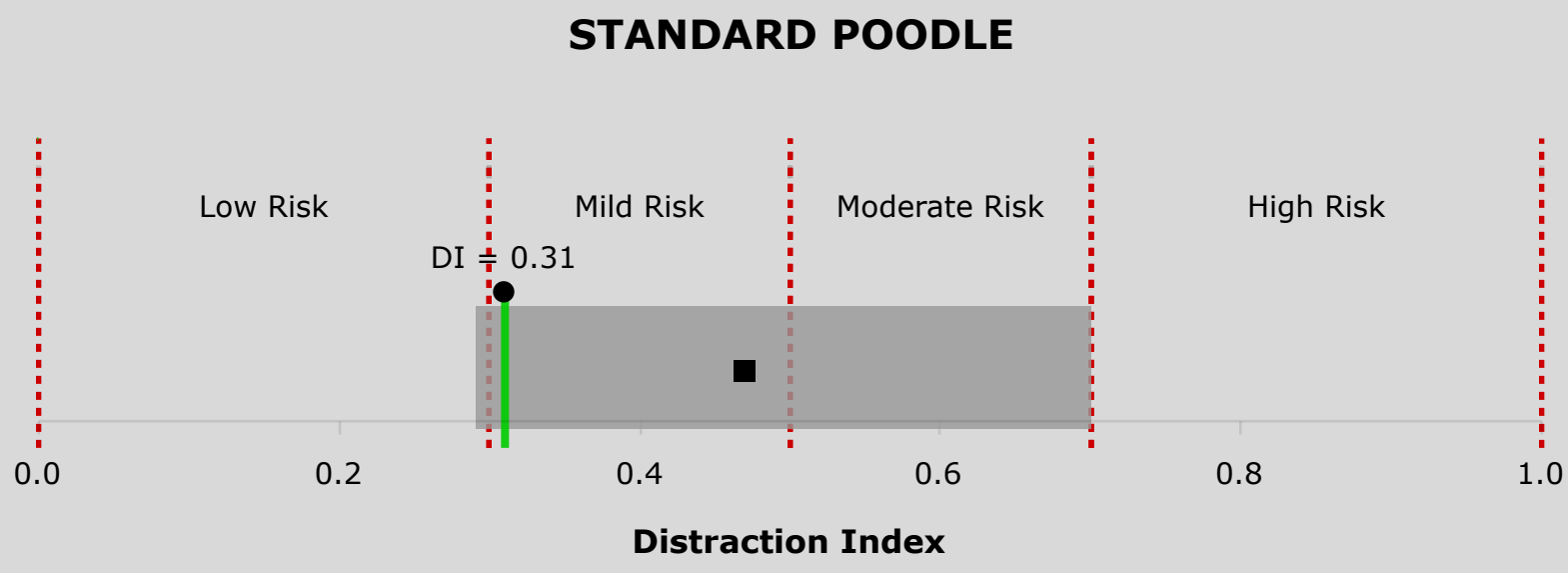
Client: Warfel, Victoria	Tattoo Num:
Patient Name: Roma	Patient ID: 4196
Reg. Name: Dream Dogz Romani Fortune	Registration Num: PR20715308
PennHIP Num: 151970	Microchip Num: 985112010075551
Species: Canine	Breed: STANDARD POODLE
Date of Birth: 23 Mar 2018	Age: 34 months
Sex: Female	Weight: 37 lbs/16.8 kgs
Date of Study: 26 Jan 2021	Date Submitted: 26 Jan 2021
Date of Report: 27 Jan 2021	

Findings

Distraction Index (DI): Right DI = 0.31, Left DI = 0.27.
 Osteoarthritis (OA): **No radiographic evidence of OA for either hip.**
 Cavitation/Other Findings: No cavitation present.

Interpretation

Distraction Index (DI): The laxity ranking is based on the hip with the greater laxity (larger DI). In this case the DI used is 0.31.
 OA Risk Category: The DI is between 0.31 and 0.49. This patient is at mild risk for hip OA.
 Distraction Index Chart:



BREED STATISTICS: This interpretation is based on a cross-section of 4332 canine patients of the STANDARD POODLE breed in the AIS PennHIP database. The gray strip represents the central 90% range of DIs (0.29 - 0.70) for the breed. The breed average DI is 0.47 (solid square). The patient DI is the solid circle (0.31).

SUMMARY: The degree of laxity (DI = 0.31) falls within the central 90% range of DIs for the breed. This amount of hip laxity places the hip at a mild risk to develop hip OA. **No radiographic evidence of OA for either hip.**